

# Lymphotaping for lymphoedema: an overview of the treatment and its uses

**Joyce Bosman**

*Joyce Bosman is Physiotherapist and Oedematherapist, Medisch Centrum Zuid, Groningen, the Netherlands*

*Email: [joyce.bosman@medischcentrumzuid.nl](mailto:joyce.bosman@medischcentrumzuid.nl)*

Medical tape has now been in existence for more than 40 years, and its uses have developed significantly during that time. The basics of the medical taping principle were developed in the 1970s in Japan, with the treatment being introduced into Europe in the late 1990s. Since then, different organisations with different names have evolved worldwide, and there are now over 500 different tapes and brand names. Modified concepts with similar techniques have also been developed.

Ruth Copee started to develop specific treatment methods for lymphoedema using tape in the US around 1995. Around the same time, Josya Sijmonsma began to do the same in Europe. Lymphotaping is now recognised to be effective in the management of lymphoedema. This article gives an overview of the concept of lymphotaping and the relevant literature.

The method is known by many different names, but the term 'medical taping concept' will be used

throughout this article to cover all taping techniques, and 'lymphotaping' will be used to refer to specific techniques for improving lymphatic function. Many of the names used in the literature refer to different companies and brand names. Each company follows different procedures for quality control, which leads to differences in properties and quality (Kumbrink, 2009). To ensure that the quality is of a high level, practitioners should use material with the EU medical device approval. Low-quality tape may influence treatment outcome and can also have adverse effects (Kumbrink, 2009). It is therefore essential for practitioners to assess and evaluate every single patient individually and then determine the appropriate taping technique and properties. Furthermore, it is strongly recommended that practitioners undergo certified training to enhance practical skills in order to be successful with this form of treatment.

## Lymphotaping: an evidence and literature overview

Medical taping concepts have only become the subject of scientific research over the last decade, as the technique is still relatively new. However, the general quality of research on lymphotaping is good. The quantity of evidence in the lymphatic field could be improved, and high-quality research into the effect of tape on blood circulation is needed (Koss and Munz, 2010). However, there are difficulties associated with this, as applying a placebo tape is a questionable procedure since there is always some level of mechanical 'input' from the tape.

Chou et al (2013) conclude that 'kinesiotaping' cannot replace short-stretch bandaging, but it can certainly be another choice for contraindicating pressure therapy patients. In their case report, Chou et al (2013) describe a breast cancer-related lymphoedema patient with arteriovenous fistula for haemodialysis who responds well to taping techniques while contraindicated for compression therapy. Like other relevant literature, Bialoszewski et al (2009) show that both lymphotaping and multilayer bandaging significantly reduce the circumference in lower-limb lymphoedema in patients

## ABSTRACT

Lymphotaping is recognised to be a promising method for use in the management of lymphoedema. This article gives an overview of the concept of lymphotaping and the relevant literature. Several methods of action are described about lymphotaping: increasing pressure differences within lymph vessels; lifting the skin (inducing opening of initial lymph vessels); connective tissue becoming more flexible; and the micromassage effect. Medical taping concepts have only become the subject of scientific research in the last decade as the technique is still relatively new. Several misunderstandings around lymphotaping therefore still exist. These are discussed, supported by the available evidence. The article demonstrates that lymphotaping is a promising technique in the treatment of lymphoedema, and should be another choice for contraindicating pressure therapy patients and in areas where compression is difficult or impossible to use. However, each patient should be assessed and evaluated thoroughly and individually so that the appropriate treatment and properties can be determined.

## KEY WORDS

- ◆ Lymphotaping ◆ Kinesiotaping ◆ Medical taping concept
- ◆ Lymphoedema ◆ Treatment

treated with the Ilizarov method, which is widely used to treat complex and/or open bone fractures (Shahid et al, 2013).

In a pilot study, Bosman and Piller (2010) posit that lymph taping decreases extracellular fluid levels and has a positive effect on a range of quality-of-life measures. While further trials are needed, this strategy is promising to better manage the incidence and severity of seroma in a conservative, non-invasive manner.

Kase et al (2003) demonstrate the effect of lymph tape on volume of blood flow using a Doppler ultrasound. Unhealthy subjects showed a significant increase in peripheral blood flow after using tape ranging from 20.6% to 60.7%. No significant differences were found in healthy patients.

Tsai et al (2009) conducted a study to compare the use of bandages and kinesiotaping in breast cancer-related lymphoedema. The results show no significant difference between both groups. However, time of application and compliance with treatment were better in the taping group. It should be noted that this study took place in Taiwan, which has a hot and humid climate. Lymph taping may be useful in such conditions where bandages can be uncomfortable.

Smykla et al (2013) also assessed the efficacy of lymph taping for treating breast cancer-related lymphoedema. Their single-blind, controlled pilot study results suggest that lymph taping in stage 2 and stage 3 lymphoedema cannot replace multilayered compression therapy and, at the moment, it should not be made an alternative choice for stage 2 and 3 breast cancer-related lymphoedema patients.

Vandermeeren et al (2013) demonstrate in their randomised controlled trial that lymph taping, used in liposuction areas, can accelerate haematoma resorption underneath the taped area. They posit that simply placing a tape can modify mechanical properties and prevent oedema formation. However, it was concluded that the haematoma was pushed away from the tape to a different area.

Melgaard and Delius (2013) conducted a study to compare treatment using lymph taping to decongestive lymphatic therapy in a group with breast cancer-related lymphoedema patients. The preliminary results show a comparable effect of bandage and tape, but patients who were taped had a better quality of life. There was also a significant difference in economic results in 4 weeks' worth of treatment: €1059.75 for short-stretch bandages versus €432.85 for lymph taping.

## The concept of lymph taping

Medical tape is made of elastic cotton with a hypoallergenic adhesive heat-sensitive glue layer. The material stretches up to 140% and is equal to the elasticity of human skin (Sijmonsma, 2010). The thickness and weight of the tape are comparable to that of the epidermis. Furthermore, the tape is water-resistant and can ventilate, which is very important for hot and humid areas. The tape is attached to its paper with 10% pre-stretch and is available in different colours and measures. In its most common application, lymph taping is applied to the draining area (lymphatic territory) of the lymphoedematous limb or region (see *Figures 1, 2 and 3*).

## Application techniques

By applying the tape in a proximal-to-distal direction and positioning the body in a way that the skin is stretched during application, the lymphatic drainage system is stimulated 24 hours a day (Sijmonsma, 2010).

The base and anchors are always rounded and unstretched when applying tape. Avoid wrinkles in the tape or the skin underneath, as blisters and irritation can occur. Rub the tape lightly for a better adhesion. The tape must be applied in accordance with the anatomy of the lymphatic flow. In contrast with earlier techniques, the author suggests that the tape should be applied with 0% stretch, which means that the paper must be taken off the tape before application. After application, the tape lifts the skin, opening the lumen of the lymph capillaries and reducing the interstitial pressure. Convolutions are now created in the skin, causing the epidermis to be slightly lifted and creating some space in the dermis (Sijmonsma, 2010).

Moreover, the tape acts as a conductor of interstitial fluid, moving fluids from areas of higher pressure towards areas of lower pressure (Kase et al, 2003). The direction of action of the tape is the opposite of the tape direction. The tape may also influence the deeper lymphatic system and encourage myofascial release, enhancing drainage in the subfascial lymphatics (although this remains to be proven). It is suspected that taping causes a movement in fascia structures, which stimulates dilatation and contraction of lymphangions. Therefore, fascial stretching provoked by tape may also influence the lymphatic system.

Another advantage of lymph taping is the potential to use the body's full range of movement. Full range of movement improves the ability to conduct aerobic exercise. The Lymphoedema Framework (2006) claims that gentle resistance exercises stimulates the muscle pump and increases lymphatic flow. These factors are extremely important in the management of lymphoedema and can be ensured by retaining full range of movement while taping. Furthermore, during movement, the convolutions created by the tape will constantly increase and decrease. This can be thought of as a kind of micro-massage effect.

## Removal techniques

The tape also needs to be removed carefully. Practitioners should moisturise the tape with oil, stretch the skin and roll off the tape in the direction of hair growth. Fixate the skin that is proximal to the part being removed and do not remove with water as this will not dissolve the glue. Products such as Cavilon Durable Barrier Cream (3M) and Sterillium Hand Disinfectant (Bode) can enhance the easy removal of tape.

## Use of lymph taping on different areas of the body

Lymph taping is particularly effective in areas where compression is difficult or impossible (e.g. facial or genital lymphoedema). However, it should always be used

in addition to decongestive lymphatic therapy, rather than as a substitute. It is to be understood as another choice in a treatment regime, applied to poor draining areas if compression is not the chosen choice of treatment. It can also be used in addition to the 'gold standard' compression (e.g. to cross watersheds). For example, in breast cancer-related lymphoedema use, tape can be applied from the heterolateral axilla into the upper arm, with compression bandaging being used for the arm. Thus, lymph taping makes it possible to work more flexibly with the stimulation of anastomosis.

To create a more intensive action, the construction can be expanded from parallel to crossed lymph taping. However, crossed lymph taping should only be used for severe forms of oedema (Sijmonsma 2010).

### Contraindications

Several contraindications have been noted for lymph taping. Taping normalises circulation, so tape on a thrombus could cause an embolism. In cases where the patient has heart or kidney problems, circulation should not be increased any further, so tape should not be applied for cases with general oedema. Caution should be used when taping directly over active malignant carcinomas. The general belief is that manual lymph drainage and, therefore, lymph taping would promote metastasis. However, a growing body of clinical evidence in now emerging showing that this is false. Given these issues, a physician should always be consulted to discuss the (dis)advantages of treatment.

Exercise caution when taping on fragile/healing skin or wounds, as the tape is not sterile. However, taping around the wound might accelerate tissue healing. Skin irritation or allergy may occur in the first 10 minutes after taping. If the skin is still red and itchy after 30 minutes, reconsider the diagnosis and technique used. Be careful applying tape in areas of administration of insulin with diabetics. There have been cases where the tape treatment has caused considerably reduced insulin requirement (Sijmonsma, 2010). Caution should also be used when taping a diabetic foot, as neuropathy causes patients not to feel wrinkles or blisters (Sijmonsma, 2010).

### Discussion and experiences of usage

In a comparison of patients using lymph tape and patients with short-stretch bandaging, Tsai et al (2009) showed that the taping group was more compliant to use of the tape than those with short-stretch bandages. Hot and humid conditions in combination with bandaging can be very stressful, and it is therefore advisable in these circumstances to consider taping instead of compression.

A clear benefit of taping in contrast to (or in combination with) compression is the ability to cross watersheds. The action of lymph tapes should be sought in the surface layer of the tissue, at the level of pre-lymphatic channels, initial lymph vessels and pre-collectors. The pre-lymphatic channels do not respect the watershed, and both the

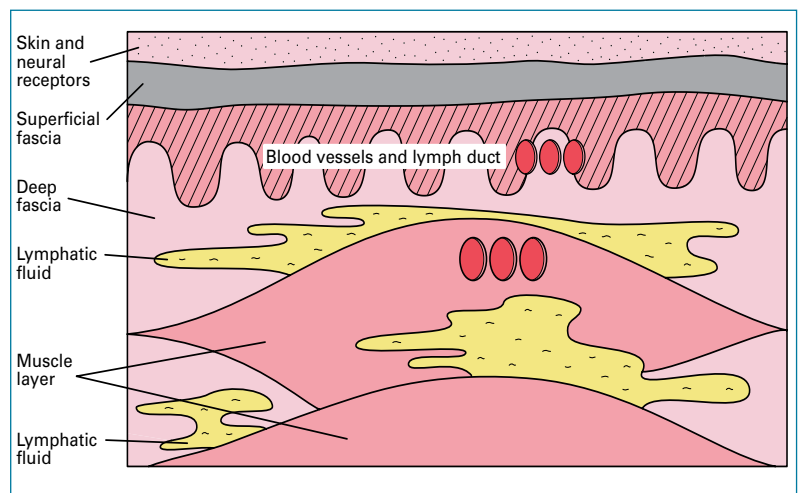


Figure 1. Lymphatic system in normal skin.

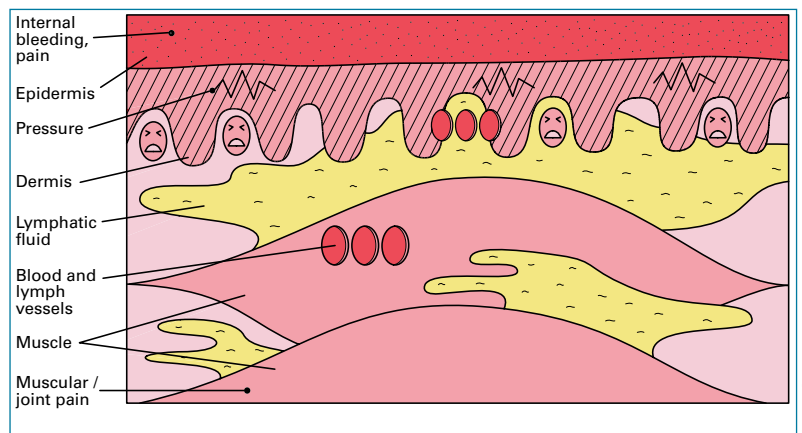


Figure 2. Compromised lymphatic system: high pressure in interstitium.

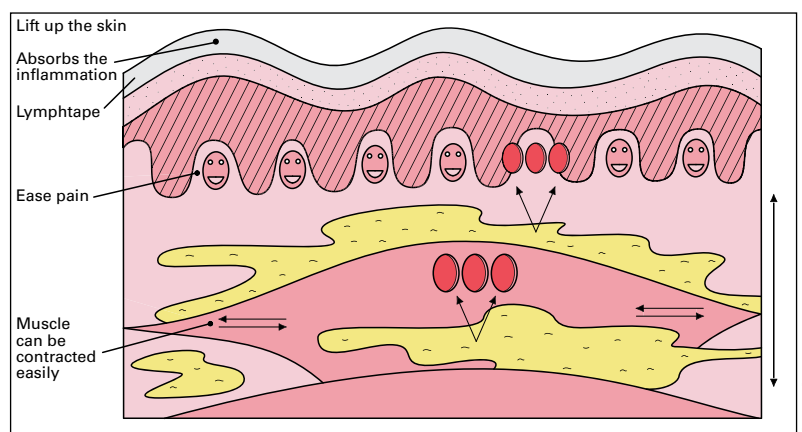
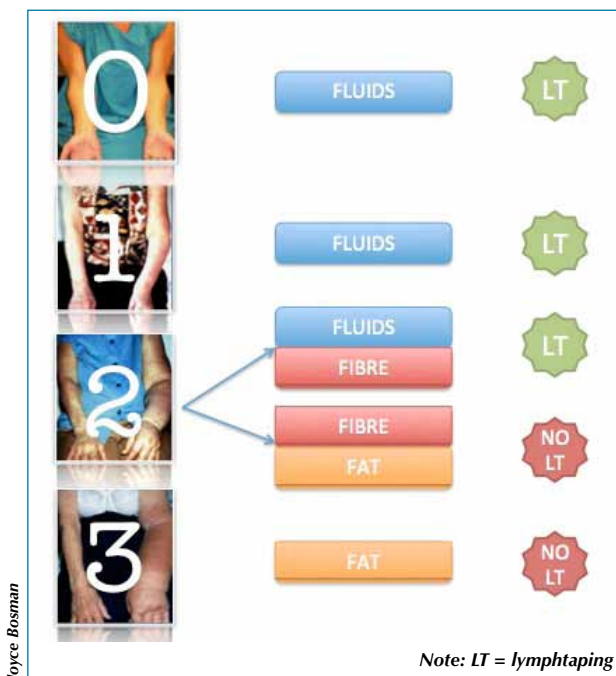


Figure 3. Concept of lymph taping.

initial lymph vessels and pre-collectors form a network where lymph drainage is possible in all flow directions. Lymph taping is therefore very effective for crossing watersheds (Sijmonsma, 2010).

### Stretching recommendations

Many therapists still use the 10% pre-stretch of the tape when applying lymph taping. However, the aim is to lift



**Figure 4. Indication for lymphtaping in different stages of lymphoedema.**

the skin, attain a slight pulling on the anchoring filaments and open up the lumen of the lymph capillaries. The only way to do this is to have sufficient stretch. Stretch is different for every person because of the ageing effect on elasticity. Therefore, in the author's opinion it is advisable only to use the stretch of the people's own skin and not to put extra pressure on the skin by stretching the tape as this arguably precludes effective results.

**Wrapping**

The goal of lymphtaping is to activate as many lymph collectors as possible. This can be achieved by wrapping the tape over a limb or the trunk. By spiralling the tape around a limb, many lymph collectors are crossed, and many pressure differences are created within these collectors, causing an increase in lymphatic flow. Analysing the concept of lymphtaping shows that it is mainly the initial lymph vessels and the pre-lymphatic channels that are influenced by lymphtaping. Therefore, the base of a tape construction does not necessarily have to be positioned by a lymph-node station, and placement of tape would not affect a lymph node directly. However, several applications of the tape that run from a lymph-node station to another lymph-node station are still used in practice, because a long strip of tape provides a longer pathway and, hence, better results in terms of a larger reabsorption area.

**Stages of lymphoedema**

According to the International Society of Lymphology (2009), there are four stages of lymphoedema. Each stage has its own tissue characteristics. Stages 0 (subclinical lymphoedema) and 1 consist mainly of fluids. Fluids in early stage 2 lymphoedema have already shifted into

fibrotic tissue, and late stage 2 and stage 3 lymphoedema mainly consist of fatty tissue (Brorson, 2010).

The effect of lymphtaping lies in the absorption of fluids in the initial lymphatics. Therefore, it would be naive to assume that lymphtaping still has an effect in late stage 2 or stage 3 lymphoedema (see Figure 4). Smykla et al (2013) confirm this in their single-blind controlled pilot study.

**Tape styles**

In the relatively short history of lymphtaping, treatment was first given by using fan-shaped tape, also known as 'spiders'. There has been a constant search for tape forms that can further improve the results. One of these forms is single strips. The disadvantage of fan-shaped tape is that irritation always occurs without exception under the base of the tape, whereas this hardly ever occurs with single strips. Furthermore, in fan-shaped taping, the accumulation of fluids occurs in one small area at the base of the tape, whereas with single strips, oedema is absorbed over a larger area since there are several different, smaller bases. Tape strips are applied without a break, so much more flexibility is possible in forming the total tape construction. If necessary, one tape strip can be removed from the construction without damaging the rest of the tape. However, application of single strips requires slightly more experience than fan-shaped tape (Sijmonsma, 2010).

**Punch tape**

Punch tape is a fairly new material used to treat lymphoedema and scars, although, due to the current minimal scientific evidence, the material has not been mentioned so far in this discussion. The perforations give this tape a greater capacity for stretching (Figure 5). The skin and fascia are stimulated in the area of the punch tape's perforations, and the skin has more scope for ventilation. Although more evidence is needed in this area, it is a promising new material, useful particularly for hot and humid areas, and very time-efficient in the sense that cutting the tape is not necessary.

**Other lymphtaping methods**

Several other lymphtaping methods can also be used for lymphoedema patients that have not yet been mentioned in this article. The focus so far has been solely on moving fluids, but, in order to be comprehensive, the other effects will be explained briefly. These actions require different techniques and, again, special certified training should be obtained before applying these techniques.

Using fully stretched tape enables scars and fibrotic tissue to be treated. This often obstructs lymphatic drainage and is therefore extremely important to treat. Furthermore, muscle function can be improved by tone regulation (e.g. trapezius, deltoid, etc.) using the muscular technique. Tense and contracted muscles can also influence lymphatic drainage. Finally, taping can be used for posture correction, supporting joint function (proprioception and stability in head, neck, shoulders, trunk, etc.).

## Conclusion

Lymph taping is a promising technique in the treatment of lymphoedema. The general quality of research on lymph taping is good. However, the quantity of evidence in the lymphatic field is lacking.

It is important to apply the correct technique when treating patients. It is therefore highly recommended that practitioners receive special certified training to enhance practical skills in order to be successful with this form of treatment. Lymph taping should form part of decongestive lymphatic therapy and can be another choice for contraindicating pressure therapy patients and in areas where compression is difficult or impossible to use. This form of treatment is also suitable for hot and humid conditions. The technique should be perceived not as a substitute, but rather as an addition to traditional treatment plans. Every patient should be thoroughly individually assessed and evaluated before the appropriate treatment and properties can be determined. **BJCN**

- Bialoszewski D, Wozniak W, Zarek S (2009) Clinical efficacy of kinesiology taping in reducing edema of the lower limbs in patients treated with the Ilizarov method. *Ortop Traumatol Rehabil* **11**(1): 46–54
- Bosman J, Piller N (2010) Lymph taping and seroma formation post breast cancer. *J Lymphoedema* **5**(2): 12–21
- Bronson H (2010) From lymph to fat: complete reduction of lymphoedema. *Phlebology* **25**(1): 52–63
- Chou YH, Li SH, Liao SF, Tang HW (2013) Case report: manual lymphatic drainage and kinesio taping in the secondary malignant breast cancer-related lymphoedema in an arm with arteriovenous (A-V) fistula for hemodialysis. *Am J Hosp Palliat Care* **30**(5): 503–6. doi: 10.1177/1049909112457010
- International Society of Lymphology (2009) The diagnosis and treatment of peripheral lymphedema: 2009 Consensus Document of the International Society Of Lymphology. *Lymphology* **42**: 53–4
- Lymphoedema Framework (2006) *Best Practice for the Management of Lymphoedema: International Consensus*. <http://tinyurl.com/oerc5td> (accessed 4 March 2014)
- Kase K, Wallis J, Kase T (2003) *Clinical Therapeutic Applications of the Kinesio Taping Method*. Kinesio Taping Association, Tokyo
- Koss J, Munz J (2010) What is the current level of evidence and the efficacy of medical taping on circulation, muscle function, correction, pain and proprioception? Literature review, European School of Physiotherapy, Hogeschool van Amsterdam. <http://tinyurl.com/qj7f5vl> (accessed 4 March 2014)
- Kumbrink B (2009) *K-Taping*. Springer, Heidelberg
- Melgaard D, Delius R (2013) How is the effect of treating secondary lymphoedema after breast cancer with kinesiotextape compared with complete decongestive therapy? 24th International Society of Lymphology Congress, Rome, 2013. <http://tinyurl.com/p6uvphm> (accessed 4 March 2014)



Fysiotape BV. Used with permission

Figure 5. An example of punch tape.

- Shahid M, Hussain A, Bridgeman P, Bose D (2013) Clinical outcomes of the Ilizarov method after an infected tibial non union. *Arch Trauma Res* **2**(2): 71–5
- Sijmonsma J (2010) *Lymph Taping*. Fysionair, Hof van Twente
- Smykla A, Walewicz K, Trybulski R et al (2013) Effect of kinesiology taping on breast cancer related lymphoedema: a randomized single-blind controlled pilot study. *Biomed Res Int* **2013**: 767106
- Tsai HJ, Hung HC, Yang JL, Huang CS, Tsao JY (2009) Could kinesio tape replace the bandage in decongestive lymphatic therapy for breast-cancer-related lymphoedema? A pilot study. *Support Care Cancer* **17**(11): 1353–60
- Vandermeeren L, Belgrado JP, Pierre P et al (2013) Lympho-taping to reduce hematoma after liposuction: a double blind clinical randomised trial, preliminary results. *Proceedings of the XXXIX Congress of European Society of Lymphology*.

## LEARNING POINTS

- ◆ Thickness and weight of the tape are comparable to that of the epidermis
- ◆ The tape lifts the skin slightly, opening the lumen of the lymph capillaries and reducing the interstitial pressure
- ◆ Lymph taping is particularly effective in areas where compression is difficult or impossible (e.g. facial or genital lymphoedema)
- ◆ The initial lymph vessels and pre-collectors form a network where lymph drainage is possible in all flow directions, so lymph taping is effective for crossing watersheds
- ◆ Lymph taping is not a substitute for 'gold standard' compression, but is an effective addition to traditional treatments